



A Rare Cause of Abdominal Pain: Primary Epiploic Appendagitis (PEA)

Karın Ağrısının Nadir Bir Sebebi: Primer Epiploik Apendajitis

A Case Report: Primary Epiploic Apendagitis

Gulbanu Erkan¹, Cem Gezen², Sabriye Sennur Bilgin³

¹Department of Internal Diseases, Gastroenterology, ²Department of General Surgery, ³Department of Radiology, İstanbul Medipol University Medical School, İstanbul, Turkey

This case report was presented at the 32th National Gastroenterology week in 25-29 November 2015, Antalya, Turkey as a poster presentation. This case report has not been previously published full text, and it is not under consideration for publication elsewhere.

Özet

Primer epiploik apendajitis (PEA), epiploik apendiksleri drene eden santral venin torsiyon yada spontan trombozu sonucu gelişen nadir bir hastalıktır. Sıklıkla kendini sınırlar ve cerrahi tedavi gerektirmez, ancak cerrahi girişim yada agresif medikal tedavi gerektiren appendisit, divertikülit yada kolesistit gibi tabloları taklit edebilir. Akut karın ağrısıyla başvuran hastalarda gereksiz cerrahi girişimi önlemek adına PEA akılda bulundurulmalıdır. Biz de karın ağrısıyla başvuran ve PEA tanısı alan bir olgumuzu sunacağız.

Anahtar Kelimeler

Karın Ağrısı; Primer Epiploik Apendajitis; Tomografi

Abstract

Primary epiploic appendagitis (PEA) is a rare disease caused by torsion or spontaneous thrombosis of the central vein that drains epiploic appendages (EA). Primary Epiploic Appendagitis (PEA) is an ischemic infarction. Although PEA is a self-limiting disease and does not require surgical intervention in most cases, it may mimic diseases that require surgical intervention or aggressive medical therapy, such as appendicitis, diverticulitis, or cholecystitis. In order to avoid unnecessary surgical intervention, PEA should be kept in mind when patients present with acute abdominal pain. In this report, we present a PEA case admitted with abdominal pain.

Keywords

Abdominal Pain; Primary Epiploic Apendagitis; Computed Tomography

DOI: 10.4328/JCAM.4436

Received: 24.02.2016 Accepted: 15.03.2016 Printed: 01.07.2016

J Clin Anal Med 2016;7(4): 567-9

Corresponding Author: Gulbanu Erkan, İstanbul Medipol Üniversitesi Tıp Fakültesi Hastanesi (Medipol Mega) TEM Avrupa Oto Yolu Göztepe Çıkışı No:1, 34214, İstanbul, Turkey. E-Mail: gcanbaloglu@yahoo.com

Introduction

Epiploic appendages (EA) are pedunculated structures filled with fat and situated along the external aspect of the colon. EA occur all along the entire colon but are mainly present in the transverse and sigmoid parts of the colon. On average, approximately 50 to 100 appendages can be present in an adult colon. Epiploic Appendagitis is a rare, self-limiting, inflammatory disease of EA. Primary Epiploic Appendagitis (PEA) is an ischemic infarction caused by torsion or spontaneous thrombosis of the central vein that drains EA (1). Secondary epiploic appendagitis (SEA) occurs when the epiploic appendage is inflamed due to another abdominal inflammatory process, such as acute appendicitis, diverticulitis, or cholecystitis. In primary epiploic appendagitis (PEA), no inflammation is present in other abdominal organs (1). Keeping PEA in mind in patients presenting with acute abdominal pain is of prime importance for avoiding unnecessary laparotomy and surgical intervention.

Case Report

A 67-year-old woman presented with a sudden severe pain in the left lower quadrant. Arrhythmia was detected in the physical examination, and defense and rebound tenderness were positive in the left lower quadrant. Patient history revealed that the patient had had atrial fibrillation and had been hospitalized in the intensive care unit due to an acute thrombotic cerebrovascular event three weeks earlier. The patient was using a proton pump inhibitor and rivaroxaban. Whole blood count revealed a normal white blood cell (WBC) count, sedimentation of 39 mm/h, and a CRP of 26 mg/L. Direct abdominal X-ray revealed no air-fluid level or perforation. Due to the suspicion of mesenteric ischemia or acute diverticulitis, oral intake was discontinued and the patient was given intravenous fluid and antibiotic therapy (ciprofloxacin and metronidazole). An emergency abdominal CT scan revealed a circular wall thickening of the distal descending colon, hypodense central area surrounded by a hyperdense ring in the paracolic fatty tissue, and an impression of fatty tissue inflammation in the most external part, consistent with PEA (Figures 1 and 2). No signs of acute mesenteric ischemia

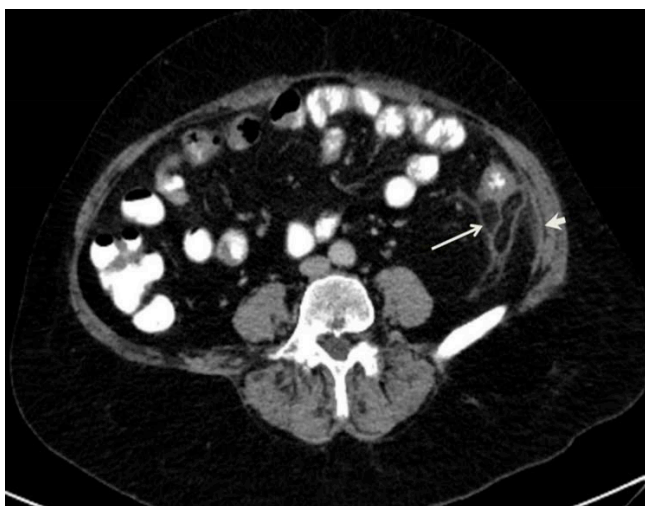


Figure 1. An oval lesion (arrow) with an impression of peripheral rim which appears hypodense due to central fat density and hyperdense due to serosal inflammation is seen which suggests the presence of epiploic appendicitis in the posterior of the descending colon. Linear density suggestive of thrombotic structure in the central part of the lesion and wall thickening caused by inflammation in the adjacent peritoneum are visible (arrow head).

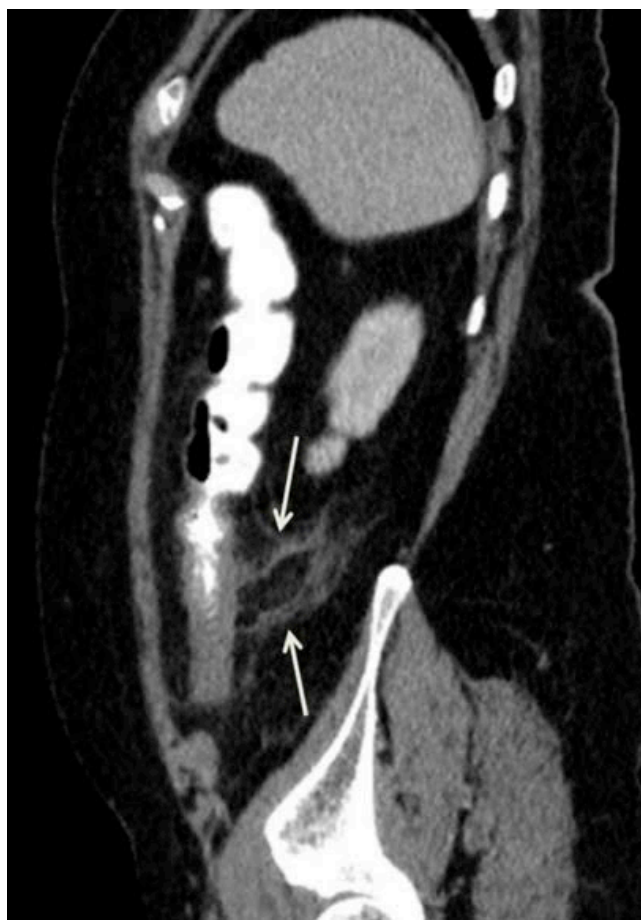

Figure 2. An oval lesion with an impression of peripheral rim which appears hypodense due to central fat density and hyperdense due to serosal inflammation is seen which suggests the presence of epiploic appendicitis in the posterior of the descending colon, and staining is viewed in the fat planes around the lesion.

or acute diverticulitis were detected. Following clinical improvement, the patient was discharged and outpatient clinic follow-up was recommended. Colonoscopy revealed normal findings 4 weeks following the initial abdominal findings.

Discussion

Appendicitis epiploica (AE), also known as epiploic appendagitis, hemorrhagic epiploitis, or epiplopericolitis, is a self-limiting rare clinical condition (1). Primary epiploic appendagitis (PEA) results from torsion or spontaneous thrombosis of the central vein that drains EA (1). The exact prevalence of PEA remains unknown since the disease is highly rare and self-limiting. PEA may affect any age group but is more commonly seen in the fourth and fifth decades. PEA is more common in men than in women (1).

PEA patients commonly present with acute-onset and well-localized abdominal pain. The pain is mostly located in the left lower quadrant (60-80%) but may also be present in the right lower quadrant (2,3). Some patients may also present with subfebrile fever. Abdominal physical examination mostly reveals palpation, localized tenderness, and defense. WBC count, sedimentation, and CRP may be normal or slightly increased (4).

The diagnosis of PEA is mostly by chance, commonly established during the imaging-based diagnosis of patients presenting with an acute abdominal pain (1). It should also be considered when explorative laparotomy fails to reveal any other common cause of acute abdomen. Abdominal CT is the gold

standard for the diagnosis of PEA and also rules out pathologies in other abdominal organs (1). On CT, EA is normally not detected, but an inflamed EA is viewed as an oval or circular pedunculated pericolonic lesion with fat density. The lesion detected on CT is surrounded by a high-density peripheral rim and represents the inflammation in the serosal layer. A linear or focal density corresponding to the thrombotic vein may appear in the middle of the lesion. Moreover, inflamed lines may appear in the pericolonic fat tissue (1,4,5). PEA may be confused with any acute abdominal disease but mostly mimics acute diverticulitis and acute appendicitis (3).

Knowledge about the treatment of PEA is highly limited and relies solely on case reports or case series. The most common treatment method is the conservative approach with anti-inflammatory drugs or short-term opiates (acetaminophen/codeine) (3,4,6). Antibiotic use and hospitalization is usually not required in uncomplicated cases (7). Surgical treatment is performed in patients not responding to the conservative approach or in patients developing complications, such as intussusception, abscess, or intestinal obstruction (8).

In conclusion, PEA is a rare cause of abdominal pain. In patients presenting with acute abdominal pain, PEA should be kept in mind during the differential diagnosis in order to prevent unnecessary laparotomy and surgical intervention.

Competing interests

The authors declare that they have no competing interests.

References

1. Mollà E, Ripollés T, Martínez MJ, Morote V and Roselló-Sastre E. Primary epiploic appendicitis: US and CT findings. *Eur Radiol* 1998;8:435-8.
2. Sandrasegaran K, Maglinte DD, Rajesh A and Akisik FM. Primary epiploic appendicitis: CT diagnosis. *Emerg Radiol* 2004;11:9-14.
3. Hwang JA, Kim SM, Song HJ, et al. Differential diagnosis of left-sided abdominal pain: primary epiploic appendicitis vs colonic diverticulitis. *World J Gastroenterol*. 2013;19(40):6842-8.
4. Rioux M, Langis P. Primary epiploic appendicitis: clinical, US, and CT findings in 14 cases. *Radiology* 1994;191(2):523-6.
5. Singh AK, Gervais DA, Hahn PF, Rhea J, Mueller PR. CT appearance of acute appendicitis. *AJR Am J Roentgenol* 2004;183(5):1303-7.
6. Vinson DR. Epiploic appendicitis: a new diagnosis for the emergency physician. Two case reports and a review. *J Emerg Med* 1999;17:827-32.
7. Sangha S, Soto JA, Becker JM, Farraye FA. Primary epiploic appendicitis: an underappreciated diagnosis. A case series and review of the literature. *Dig Dis Sci* 2004;49:347-50.
8. Bonnefoy S, Corberand D, Sinayoko L, Harnois F, Mennecier D, Thiolet C. Epiploic appendicitis: report of a case. *Gastroenterol Clin Biol* 2008;32:1092-4.

How to cite this article:

Erkan G, Gezen C, Bilgin SS. A Rare Cause of Abdominal Pain: Primary Epiploic Appendicitis (PEA). *J Clin Anal Med* 2016;7(4): 567-9.